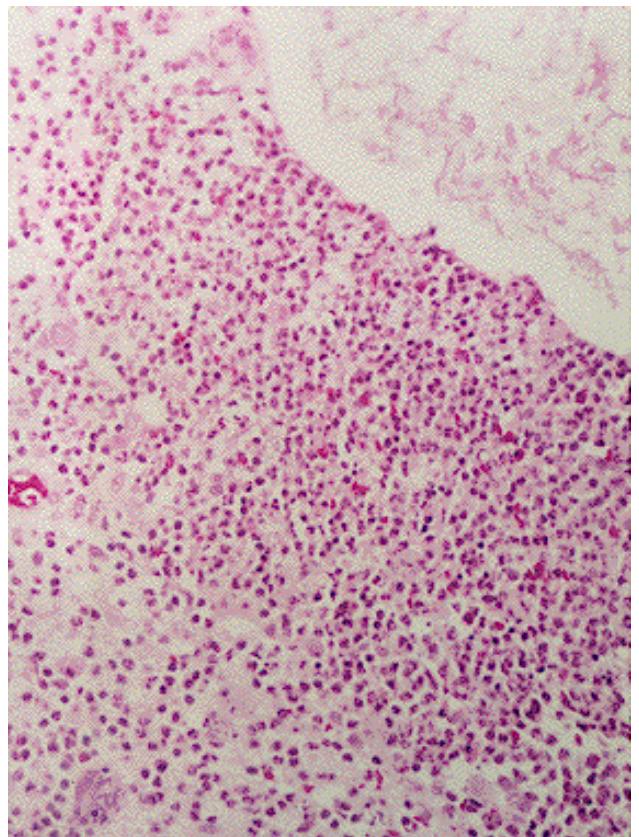


ABSCESS AND PHLEGMON

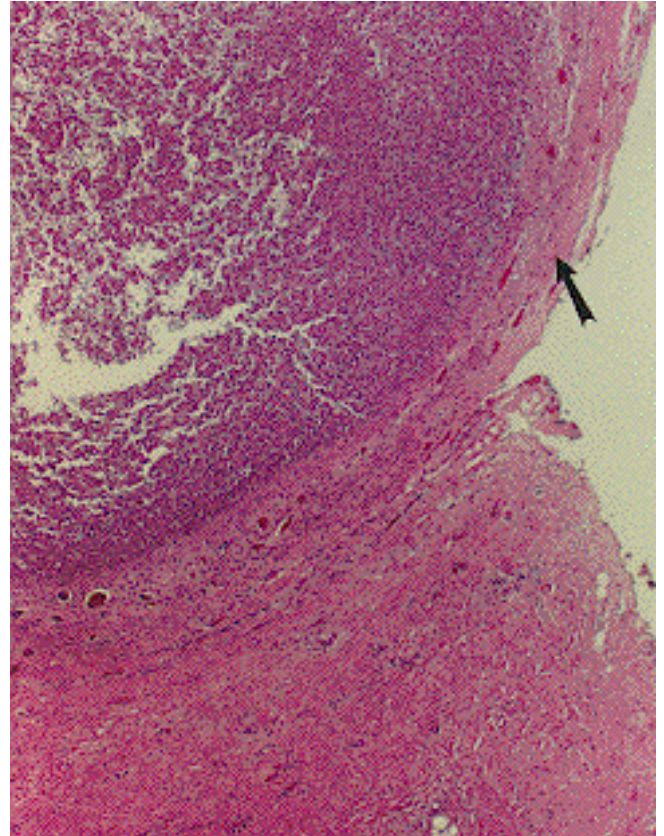
An abscess is a localized collection of pus often caused by bacteria such as staphylococcus aureus. Foreign material, fibrin, and blood clot may predispose. There is severe inflammation with masses of neutrophils, living and dead, necrotic tissue debris, and formation of granulation tissue at the periphery to wall off the abscess.

Leukocytes gather in the infected area and produce proteases that degrade dead tissue and convert it into pus. This process is termed liquefactive necrosis. The pus may discharge to the surface or if resolution occurs, there is healing with scar formation.

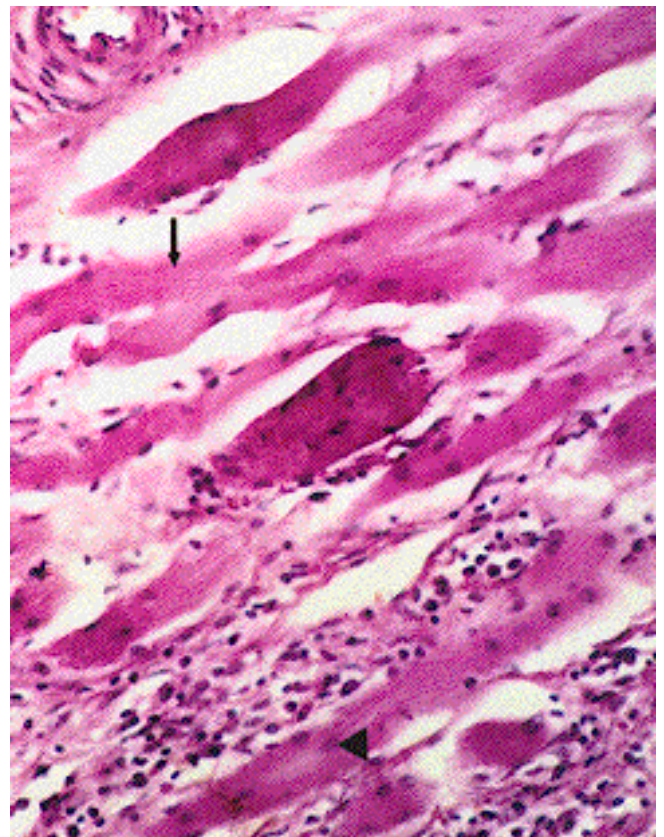
Abscess. High power shows a near pure population of neutrophils in the central portion of this abscess.

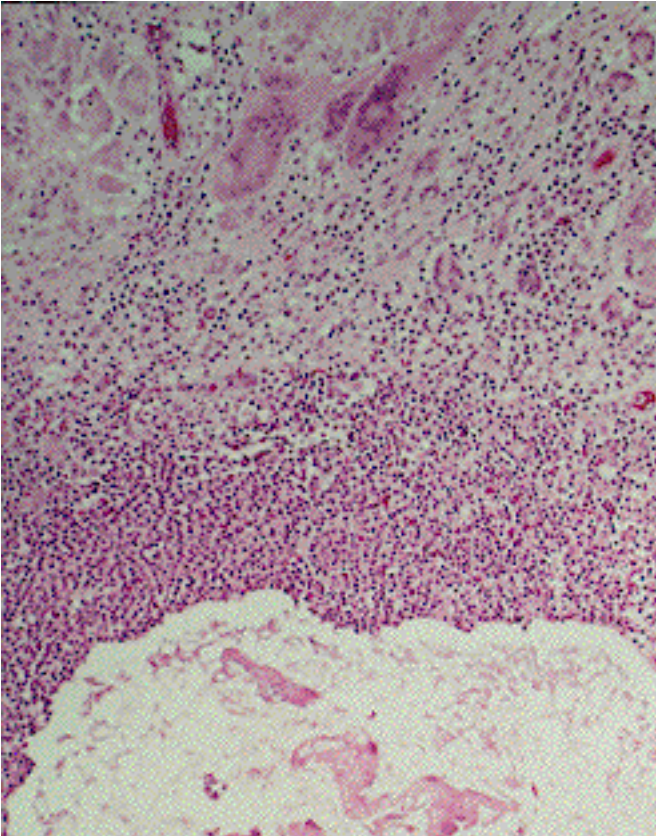


Abscess, skin. Fibrosis is present in wall (arrow) of the abscess. Suture material was seen nearby.



Phlegmon, tongue. Muscle fibers are swollen and have lost their striations (arrow). Nuclei are becoming indistinct (triangle). There is heavy infiltrate of inflammatory cells between muscle fibers.





Abscess. Intense population of neutrophils surrounds a liquid center containing keratinous debris. Numerous foreign body giant cells in periphery.

CLINICAL ASPECTS:

A common site for abscess in the head and neck area is the peritonsillar space. A peritonsillar abscess is also known as a "quinsy." Bacteria spread from an acute infection of the palatine tonsil to the potential space between the tonsil and the adjacent muscle with the resultant development of an abscess. A large abscess may literally dissect the tonsil from its bed but more commonly the abscess is less advanced. In the healing process, a marked fibrotic reaction results in dense scar that may make dissection difficult should the patient later undergo tonsillectomy.

Untreated, a peritonsillar abscess usually ruptures into the pharynx spontaneously, or slowly resolves. In rare instances, an untreated patient may develop a life-threatening situation should the peritonsillar abscess obstruct the airway, rupture with aspiration of pus, or extend into the parapharyngeal space and superior mediastinum (carotid rupture), or travel along the carotid sheath and reach the intracranial cavity resulting in cerebritis/meningitis.

Thyroglossal cysts and branchial cysts commonly develop intermittent infections with abscess formation and there are a multitude of other conditions about the head and neck predisposing to abscess.

A phlegmon results when an acute infection is not confined as in the case of abscess. Instead the infection spreads along tissue planes and between muscle fibers. Ludwig's angina is a phlegmon of the neck. In that condition, infection (usually streptococcal) comes from a mandibular tooth and produces brawny induration of the neck that may extend from mandible to clavicle and be life-threatening.