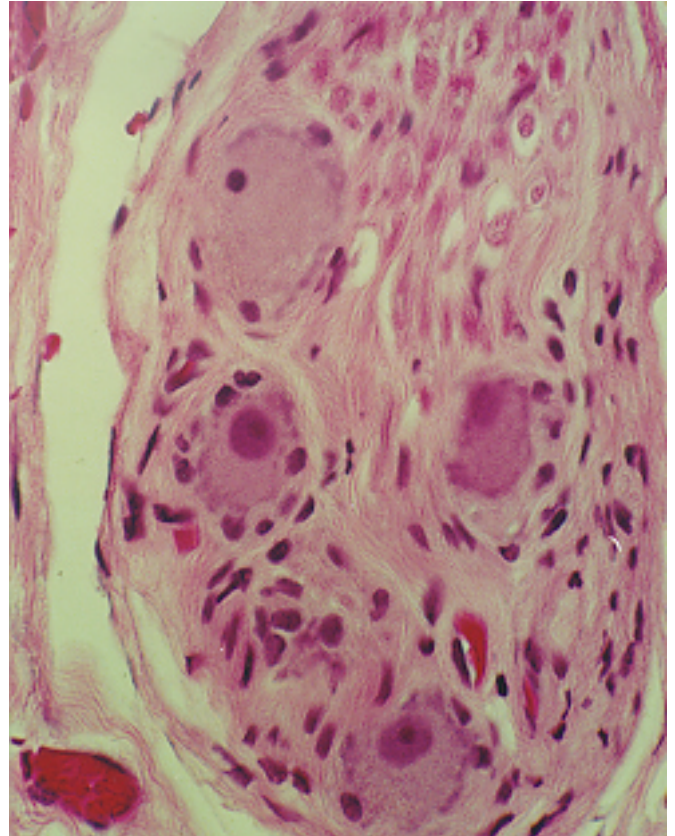
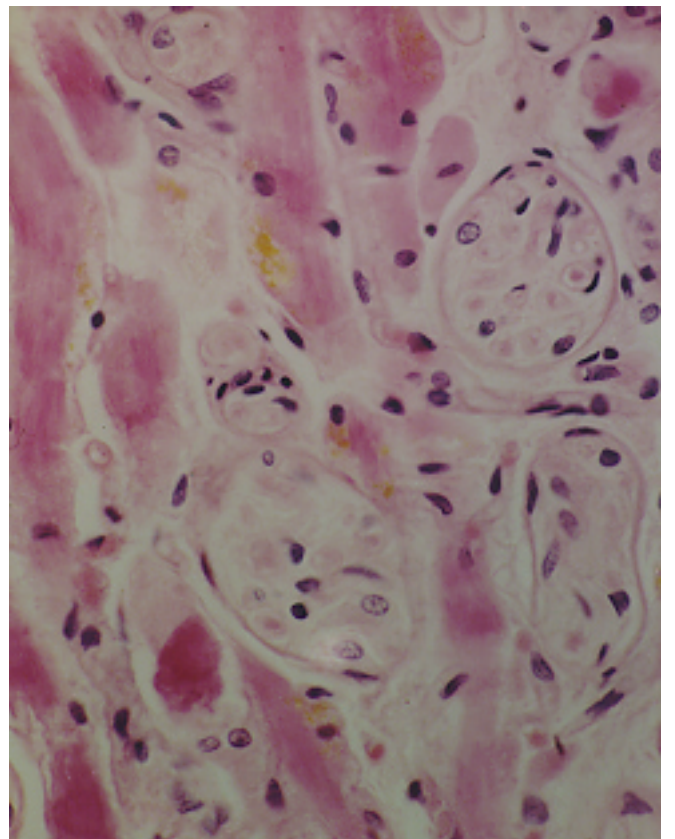


NERVE

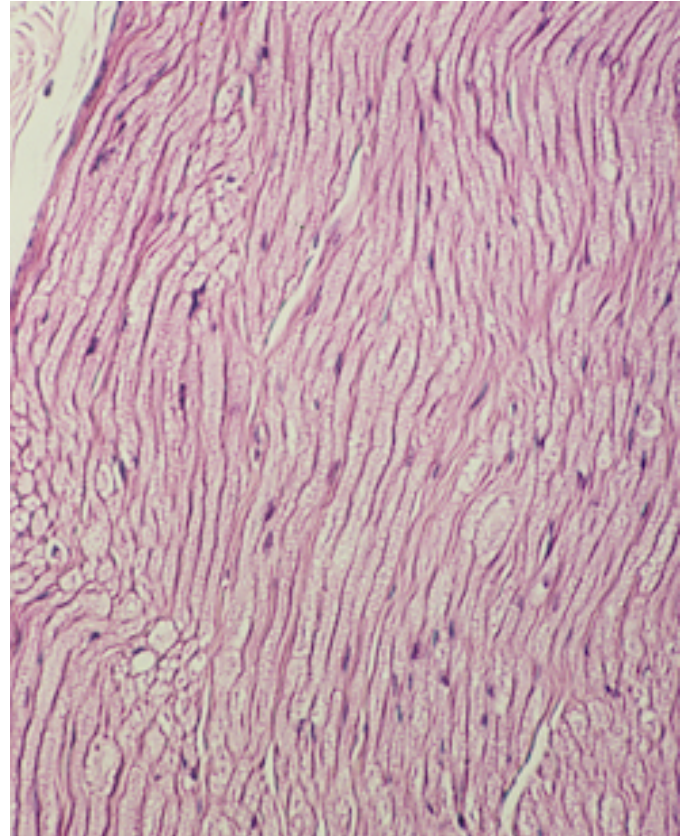
Ganglion. Ganglion cells and nerve fibers from submandibular area.



Nerve, cross section of nerves with eosinophilic extraocular muscles. Yellow pigment may be lipofuchsin.



Myelinated nerve, as seen in frozen specimen.



Nerve, longitudinal section of myelinated peripheral nerve. Note the characteristic “wavy” configuration of Schwann cell nuclei.

