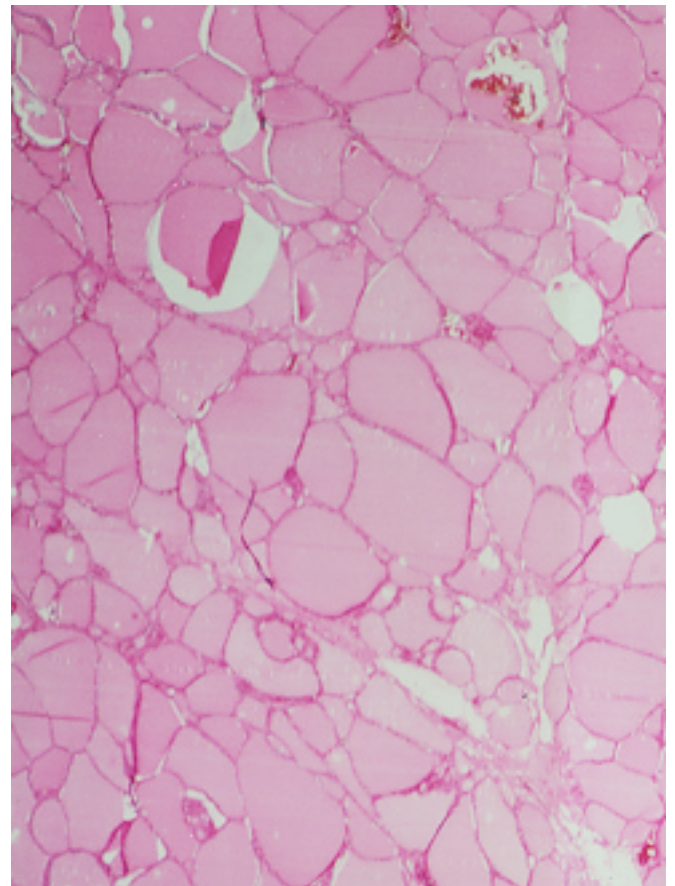


THYROID--NORMAL GLAND

The thyroid gland is covered by fibrous capsule with septa dividing it incompletely into lobules. The thyroid follicle is the functioning unit of the gland and is a closed sac lined by a single layer of epithelium. The follicles may vary in size and shape with a group of 20-40 follicles forming a lobule. The nucleus of the follicular cell is round and oval with usually a single nucleus. The cells may be flattened and look cuboidal to columnar.

Microscopically, normal thyroid tissue can be found outside the anatomic confines of the gland and in an autopsy study of fifty[©]six thyroid glands, recognizable thyroid tissue outside of the capsule was found in forty cases and in the skeletal muscle of the neck in six cases.

Normal thyroid. Numerous follicles are filled with eosinophilic colloid and lined by single cuboidal follicular cells.



THYROID TISSUE IN ECTOPIC LOCATIONS

A migration failure along the pathway of the thyroglossal duct can result in the presence of ectopic thyroid tissue anywhere between the foramen cecum at the base of the tongue and the site of the normal gland. The most common sites are lingual thyroid, sublingual thyroid and thyroid tissue as a component of thyroglossal duct cyst located usually in the thyrohyoid interval. Lingual thyroid is rare as a clinical problem but has been reported in almost ten percent of tongues examined at autopsy. Microscopically, ectopic thyroid follicles usually have a normal appearance.

Thyroid inclusions are also found in lymph nodes but this does not always indicate metastatic disease. Presence of psammoma bodies is almost a guarantee of metastasis no matter how benign the microscopic appearance. If a third or more of the node is replaced by thyroid tissue or if several nodes show thyroid tissue, the diagnosis of malignancy should be strongly entertained. There are other well documented examples of ectopic benign tissue found in lymph nodes.